



## The post-op chest

Lungs

### What will I gain from this video?

After watching this video, you will know how to recognize radiological features related to lung surgery.

### Complications related to surgery—EARLY

- Bleeding
- Persistent air leak
- Pleural effusions
- Pneumothorax
- Infection of lungs (pneumonia)
- Infection of the pleural space (empyema)
- Postoperative atelectasis or collapse

### Complications related to surgery—LATE

- Bronchopleural fistula
- Chronic empyema
- Tumor recurrence

---

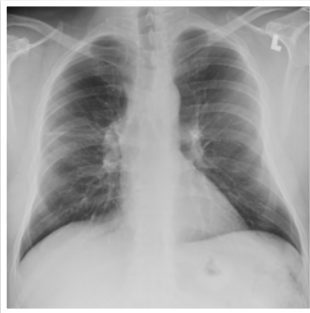
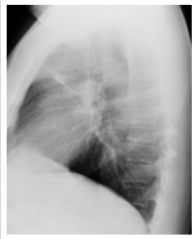
---

---

---

---

### Lungs segmentectomy



---

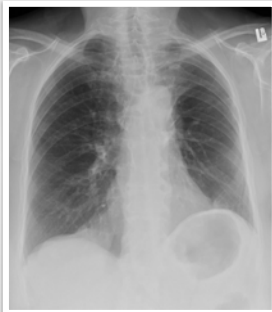
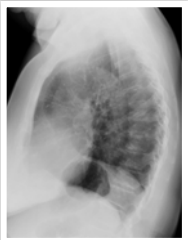---

---

---

---

### Lungs lobectomy



---

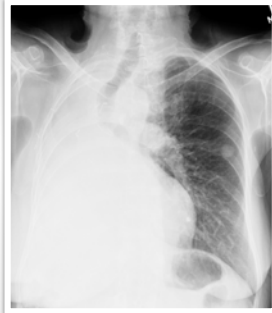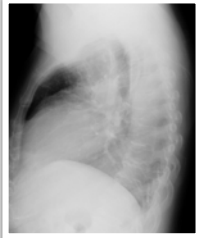---

---

---

---

**Lungs  
pneumonectomy**



---

---

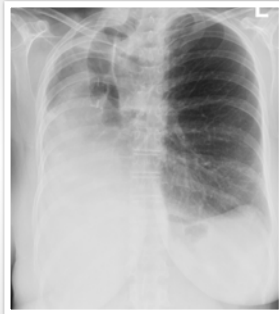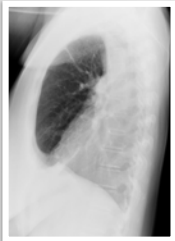
---

---

---

---

**Lungs  
pneumonectomy**



---

---

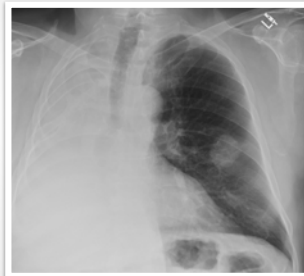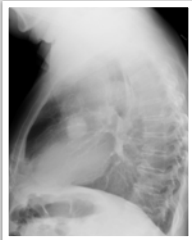---

---

---

---

**Lungs  
pneumonectomy**



---

---

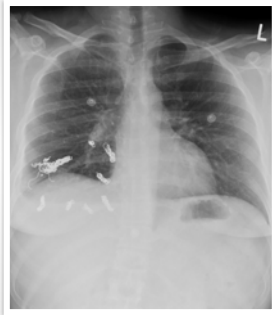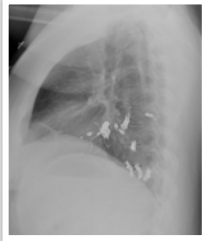---

---

---

---

Lungs  
interventional



---

---

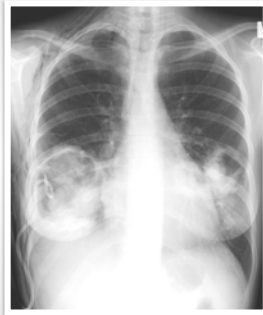---

---

---

---

Lungs  
interventional



---

---

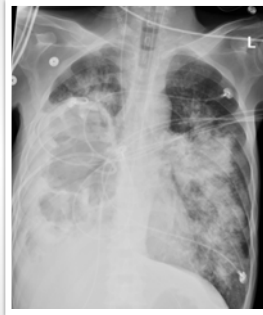---

---

---

---

Lungs  
interventional



---

---

---

---

---

---

Always compare to previous X-rays to identify complications.

Understand what type of surgery was performed.

Appearance will depend on type of surgery.

Postoperative complications can occur early and late.

---

---

---

---

---

---